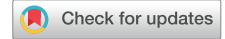

Refractory Massive Ascites: An Unusual Presentation of Nephrogenic Diabetes Insipidus



María Ignacia Pezantes¹, Paola Krall^{1,2}, Fernando Manríquez³, Ingrid Arce¹ and Leopoldo Ardiles¹

¹Department of Nephrology, Faculty of Medicine, Universidad Austral de Chile, Valdivia, Chile; ²Department of Pediatrics and Child Surgery, Faculty of Medicine, University of Chile, Santiago, Chile; and ³Institute of Medicine, Faculty of Medicine, Universidad Austral de Chile, Valdivia, Chile

Correspondence: Leopoldo Ardiles, Laboratory of Nephrology, Faculty of Medicine, Universidad Austral de Chile, Valdivia, Chile. E-mail: leopoldoardiles@gmail.com

Received 3 November 2021; revised 17 November 2021; accepted 22 November 2021; published online 8 December 2021

Kidney Int Rep (2022) 7, 647–650; <https://doi.org/10.1016/j.ekir.2021.11.027>

© 2021 International Society of Nephrology. Published by Elsevier Inc. This is an open access article under the CC BY-NC-ND license (<http://creativecommons.org/licenses/by-nc-nd/4.0/>).

INTRODUCTION

Urinary ascites is an uncommon condition mainly associated with trauma or surgical-induced urinary bladder perforation.¹ It is known that polyuric syndromes, including psychogenic polydipsia and central or nephrogenic diabetes insipidus (NDI), may induce dilation of the urinary tract and rarely chronic renal damage.^{2,S1–S3} We report the exceptional clinical case of a young man hospitalized for the study of progressive massive ascites after a lumbar trauma, who had a personal and familiar history of polyuria-polydipsia.

CASE PRESENTATION

A young man, aged 16 years old, was admitted to our hospital for the study of massive ascites requiring an abdominal drainage puncture to alleviate pain and respiratory discomfort. Approximately 4 months earlier, he had suffered lumbar trauma after a fall from a vehicle, followed by transitory macroscopic hematuria and slowly progressive abdominal distention. At admission, his vital signs were normal, without facial or distal edema and no evidence of lumbar trauma. Laboratory testing revealed a normal hematological profile, a slight increase in serum creatinine level (1.28 mg/dl), a very low urinary density (Table 1), and low urinary creatinine level (7 mg/dl). A diagnostic/therapeutic drainage of ascites was performed, revealing a clear fluid with mild hypercellularity (300 mononuclear cells × mm³), creatinine concentration of 3.26 mg/dl, and without increases in triglyceride levels. Image-nephrological studies (ultrasonography and computed contrasted tomography) revealed severe bilateral hydronephrosis without evidence of

obstructive factors but with signs of old fractures on 11° and 12° left ribs, massive ascites, and a left perirenal collection that was filled by leakage of contrast media from the renal pelvis (Figure 1a-d).

After several therapeutic paracentesis, ascites reproduced rapidly while the patient remained intensely polyuric (urinary output of 22 l/d). He recognized a long-lasting history of polyuria and polydipsia, since he could remember, having suffered school bullying because of frequent urination and enuresis. The polyuria-polydipsia condition was shared by many members of his maternal family (Figure 2). No history of treatments or drugs was obtained.

A cystoscopy examination was performed, ruling out obstructions or lesions at the low urinary tract, although a distended and trabeculated bladder was observed. A pyelovesical pig tail at the left side and a Foley catheter were inserted, with rapid resolution of the ascites, although maintaining a small perirenal collection at ultrasonography. All microbiological culture test results of the ascites fluid were negative, including mycobacteria.

Once the patient was stable, he was submitted to a short (7 hours) water deprivation test, without changes in urinary volume (700 ml/h) nor increase in urinary density (starting with 1.003 and ending with 1.002) but an increase in natremia to 154 mEq/l. No response was obtained after arginine vasopressin administration (2 nasal puffs after the test and 1 tablet every 12 hours in the following 2 days), remaining with polyuria and polydipsia, but ascites did not recur. An empirical treatment with oral hydrochlorothiazide failed, without changes in urinary volume, and we decided not to try with indomethacin.

Table 1. Results of laboratory tests at admission and discharge

Biochemical results	At admission	At discharge
Serum creatinine (mg/dl)	1.28	0.57
Uremia (mg/dl)	13	11
Serum sodium (mEq/l)	139	140
Serum potassium (mEq/l)	3.8	4.5
Serum chloride (mEq/l)	105	101
Hemoglobin (g/dl)	11.6	11.6
Serum albumin (g/dl)	3.4	4.3
Urinary density	1.002	1.002

A genetic analysis by direct sequencing of all the AVPR2 and AQP2 coding exons identified a hemizygous variant in AVPR2, c.604C>T (p.R202C), predicted to be pathogenic.³ His mother, with a long history of polydipsia and polyuria of 7 l/d, is a heterozygous carrier for the same variant.

DISCUSSION

This exceptional case illustrates the unusual diagnosis of a familiar NDI after a traumatic injury of a severely dilated urinary tract in a young man.

The high rurality, early beginning of the polyuric syndrome and coexistence of relatives with the same condition, may explain the diagnostic delay. During school, the patient had to retain voluntarily very high urine volumes that may have caused the massive chronic bladder distention, with secondary vesicoureteral reflux.

The study of the ascites fluid suggested a urinary origin because its creatinine concentrations were higher than the serum but lower than the urinary, although it was under the normal values owing to the very diluted urine. Edema was not found in other sites of the body, and no evidence of liver or other renal diseases as causes of the ascites was found. An infection of the peritoneal space was also discarded by cultures, and the mild increase in the mononuclear cells was

attributed to sterile irritation of the peritoneum by the presence of the urine.

Urinary ascites associated to traumatic or surgical injury of the urinary bladder has been reported.^{1,54} In our patient, one of the fractured ribs may have penetrated the retroperitoneal space during the trauma, wounding a dilated pelvis and creating a small communication between the retroperitoneal and peritoneal space, causing the massive ascites facilitated by the enormous urinary volumes. Only one similar case has been reported, but the cause of the urinary tract damage could not be identified.⁴ We are confident on the injury mechanism proposed in our patient because scan results revealed contrast leakage from the renal pelvis to the retroperitoneum in the vicinity of a rib fracture, and ascites resolved after the isolation of the urine fistulae with a pig tail insertion. The beginning of polyuria at childhood, the absence of drugs or other medical conditions, and the existence of affected relatives in the mother's family suggested a rare inherited condition characterized by a kidney insensitivity to arginine vasopressin with the consequent inability to concentrate the urine: hereditary NDI. This condition has been described in an X-linked form in association with changes in the gene encoding the AVPR2 or an autosomal form owing to genetic variants in the water channel AQP2, both inherited in a recessive fashion, although dominant forms have been reported.⁵⁵ Approximately 90% of the patients carry variants in AVPR2, and >250 mutations have been described until today.⁵

The AVPR2 variant carried by our patient and shared by his mother has been described previously in persons with moderate-severe NDI phenotype^{3,56}; functional *in vitro* assays have revealed that this variant has normal expression and reaches the cell surface without affecting the mRNA expression, but ligand binding activity is significantly reduced in comparison

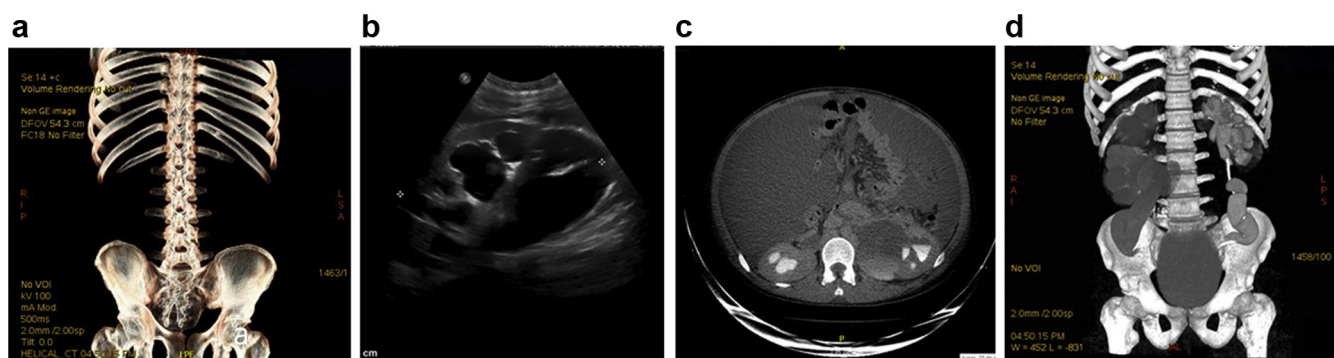


Figure 1. Bilateral hydroureteronephrosis and urinary fistula at the left pyelocaliceal area causing massive ascites. (a) Sequelae of fractures at the 11^a and 12^a left ribs. (b) Ultrasonography revealing severe dilatation of pelvis and calices of the left kidney. (c) Computed contrasted tomography showing severe ascites, dilatation of both urinary systems and extravasation of contrast media to the left perirenal space. (d) Severe distention of bladder, both ureters and pelvis and a pig tail catheter positioned at the left side.

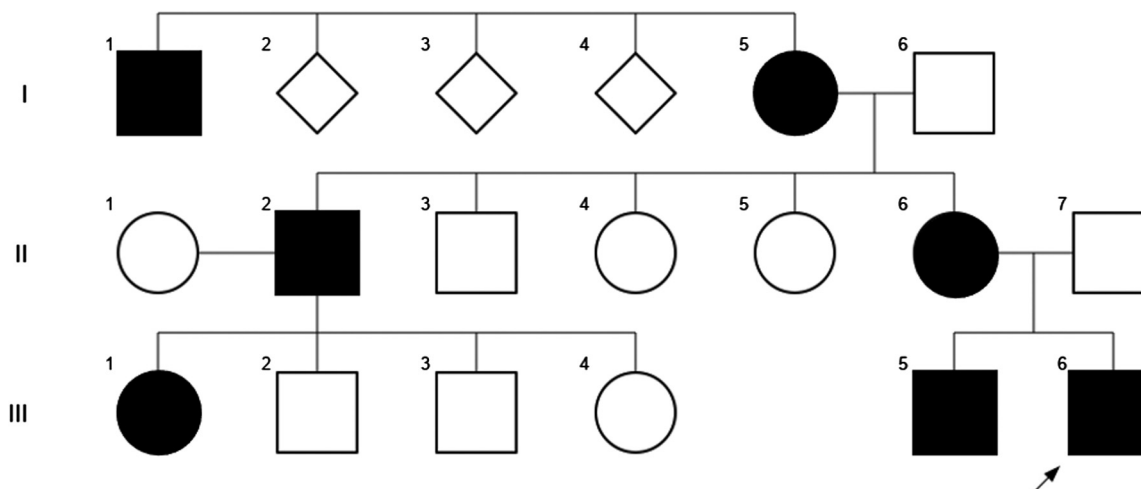


Figure 2. Familiar pedigree. Circles represent females, squares represent males, rhombuses unknowns. Individuals affected with the polyuric-polydipsic syndrome are represented as black filled symbols. An arrow identifies the index (proband) patient described in the manuscript.

to the normal protein.⁶ Altogether, missense variants represent more than half of the NDI cases. Arginine to cysteine is the most common amino acid substitution in AVPR2, and arginine, the amino acid with the highest mutability rate, is more likely to cause a clinical disease.⁷

Because vasopressin receptor genes are in the X chromosome, it is important to highlight that polyuric syndromes may be observed in women carrying these variants. Nevertheless, the random X chromosome inactivation produces a capricious degree of phenotypic expression⁵

As with most rare diseases, little long-term clinical data exist to inform management and prognosis. Previous reports have highlighted the potential complications of flow uropathy and behavioral abnormalities, such as attention deficit disorders and severe psychomotor delay, sometimes associated with intracranial calcifications.⁸ New treatment approaches for congenital NDI have been tested in animal models, but efficacy in patients has not yet been confirmed.^{9, S7, S8}

CONCLUSION

Physicians should be encouraged to follow-up families with suspected X-linked NDI and to consider early

Table 2. Teaching points

Concluding remark

Polyuric syndromes might induce massive dilatation of urinary system.

Inherited forms of NDI manifest as polyuria-polydipsia during early childhood.

AVPR2 variants are the most frequent cause of Inherited NDI.

Traumatic lesions of an hydronephrotic kidney might cause ascites syndrome if connections between retroperitoneum and peritoneal space occurred.

Any patient with blunt abdominal trauma and macroscopic hematuria should undergo formal assessment including contrast assisted cross sectional imaging to assess for renal and ureteric injury.

NDI, nephrogenic diabetes insipidus.

genetic testing of symptomatic relatives, (pre)symptomatic females, or at-risk male infants to prevent dehydration associated with significant morbidity and mortality, provide advice on double voiding to reduce further dilatation of the urinary tract, and perform regular ultrasound surveillance. The main teaching messages are found in Table 2.

DISCLOSURE

All the authors declared no competing interests.

PATIENT CONSENT

The authors declare that they have obtained consent from the patient discussed in the report

ACKNOWLEDGMENTS

MIP is a resident fellow of the Nephrology Program, Faculty of Medicine, Universidad Austral de Chile.

SUPPLEMENTARY MATERIAL

Supplementary File (PDF)

Supplementary References.

REFERENCES

1. Matsumura M, Ando N, Kumabe A, Dhaliwal G. Pseudo-renal failure: bladder rupture with urinary ascites. *BMJ Case Rep*. 2015;2015:bcr2015212671. <https://doi.org/10.1136/bcr-2015-212671>
2. Shapiro SR, Woerner S, Adelman RD, Palmer JM. Diabetes insipidus and hydronephrosis. *J Urol*. 1978;119:715-719. [https://doi.org/10.1016/s0022-5347\(17\)57608-9](https://doi.org/10.1016/s0022-5347(17)57608-9)
3. Bichet DG, Birnbaumer M, Lonergan M, et al. Nature and recurrence of AVPR2 mutations in X-linked nephrogenic diabetes insipidus. *Am J Hum Genet*. 1994;55:278-286.
4. Zender HO, Ruedin P, Moser F, Bolle JF, Leski M. Traumatic rupture of the urinary tract in a patient presenting nephrogenic diabetes insipidus associated with hydronephrosis and

- chronic renal failure: case report and review of the literature. *Clin Nephrol.* 1992;38:196–202.
5. Bichet DG. Genetics in endocrinology pathophysiology, diagnosis and treatment of familial nephrogenic diabetes insipidus. *Eur J Endocrinol.* 2020;183:R29–R40. <https://doi.org/10.1530/EJE-20-0114>
 6. Tsukaguchi H, Matsubara H, Taketani S, Mori Y, Seido T, Inada M. Binding-, intracellular transport-, and biosynthesis-defective mutants of vasopressin type 2 receptor in patients with X-linked nephrogenic diabetes insipidus. *J Clin Invest.* 1995;96:2043–2050. <https://doi.org/10.1172/JCI118252>
 7. Spanakis E, Milord E, Gagnoli C. AVPR2 variants and mutations in nephrogenic diabetes insipidus: review and missense mutation significance. *J Cell Physiol.* 2008;217:605–617. <https://doi.org/10.1002/jcp.21552>
 8. Sharma S, Ashton E, Iancu D, et al. Long-term outcome in inherited nephrogenic diabetes insipidus [published correction appears in *Clin Kidney J.* 2020;13:1111]. *Clin Kidney J.* 2019;12:180–187. <https://doi.org/10.1093/ckj/sfy027>
 9. Bockenhauer D, Bichet DG. Pathophysiology, diagnosis and management of nephrogenic diabetes insipidus. *Nat Rev Nephrol.* 2015;11:576–588. <https://doi.org/10.1038/nrneph.2015.89>